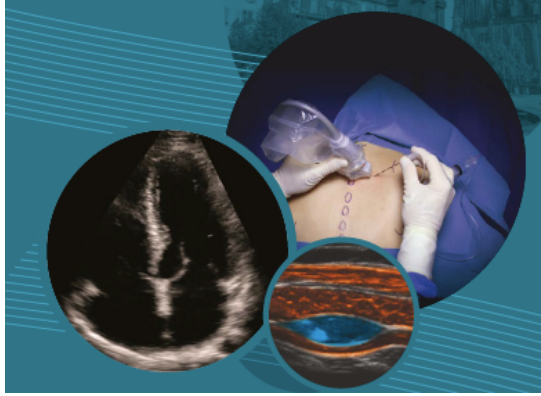

Total Ultrasound Body Examination

○ Péridurale thoracique et approche ultrasonique	*Dr Christophe AVELINE*
○ Je ne trouve d'abord veineux et je dois lui mettre une artère…	*Dr Paul ZETLAOUI*
○ Hypoxie en SSPI: approche diagnostique ultrasonique	*Dr Laurent ZIELESKIEWICZ*
○ Dysfonction périopératoire – ETO	*Dr Ivan PHILIP*

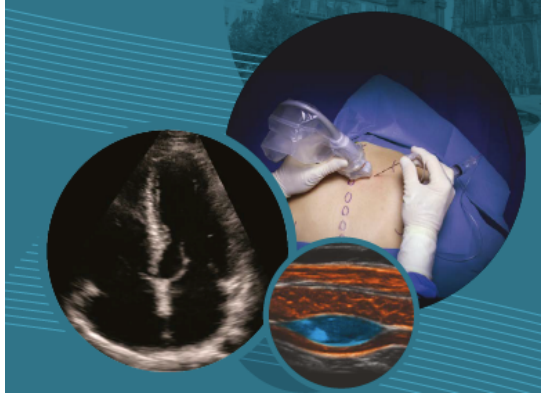

Complexité anatomique (vs rachis lombaire)

Lombaire

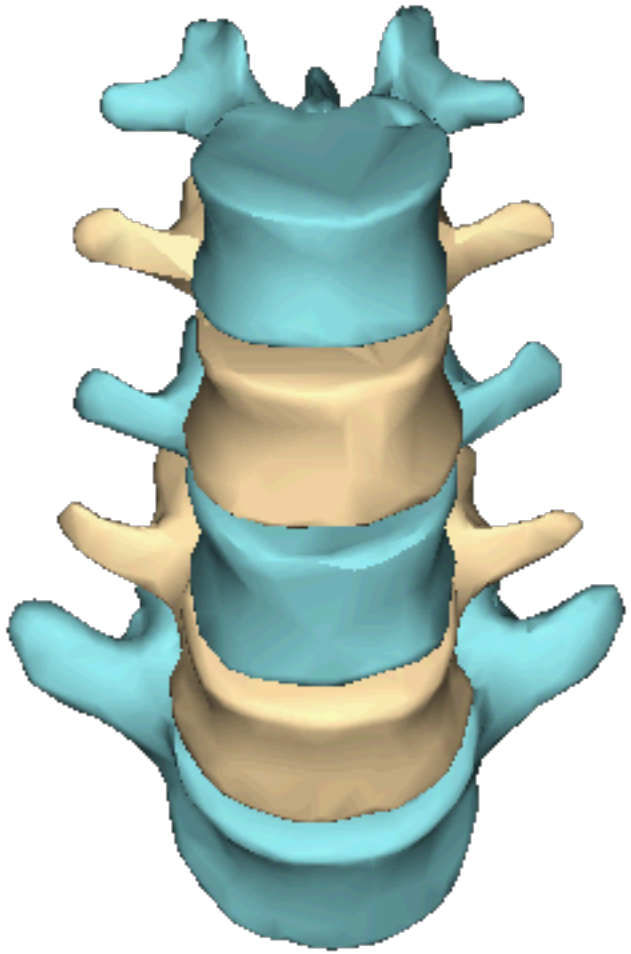

Thoracique

Approche paramédiane sagittale oblique

Lombaire

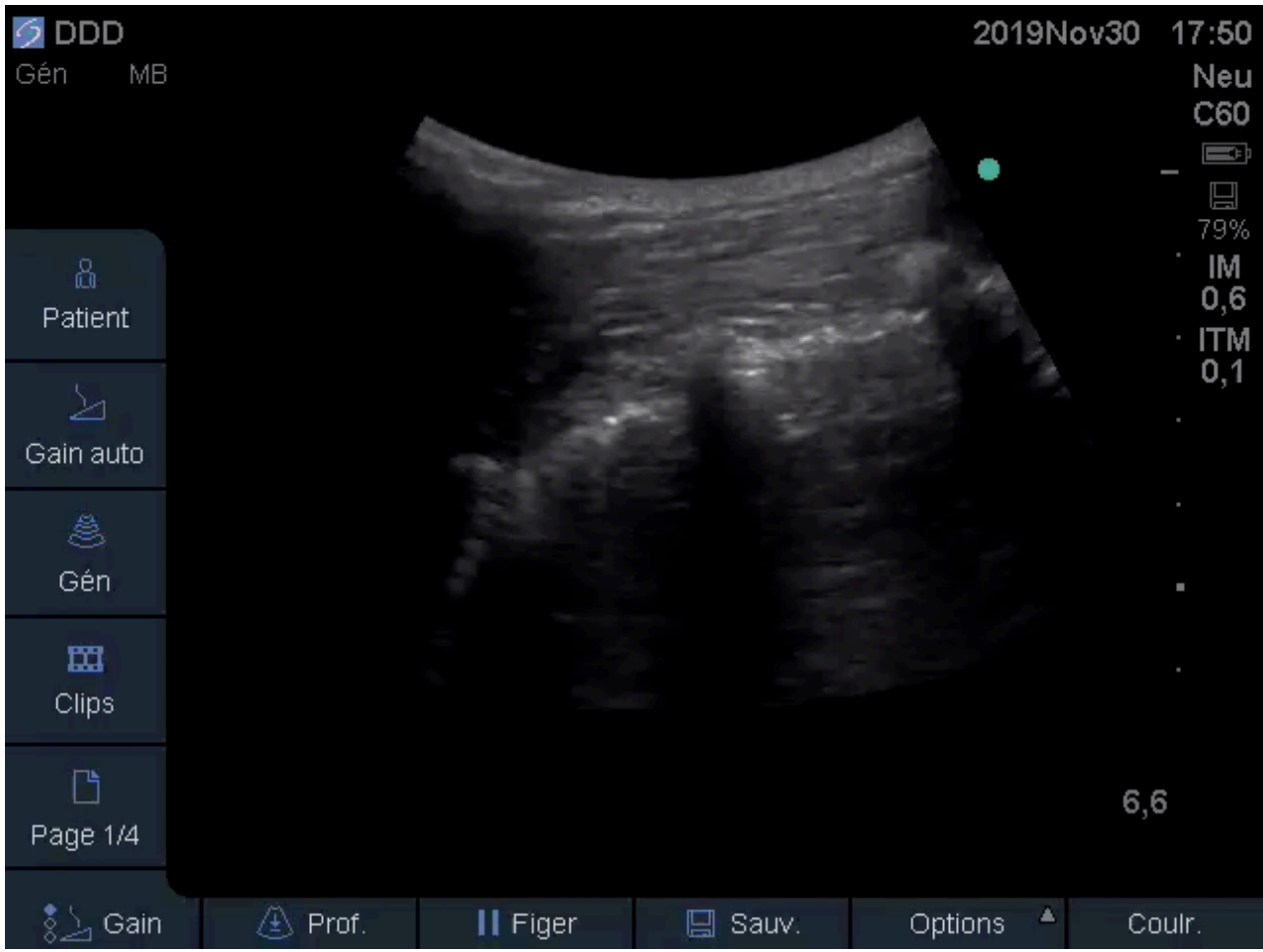

Thoracique

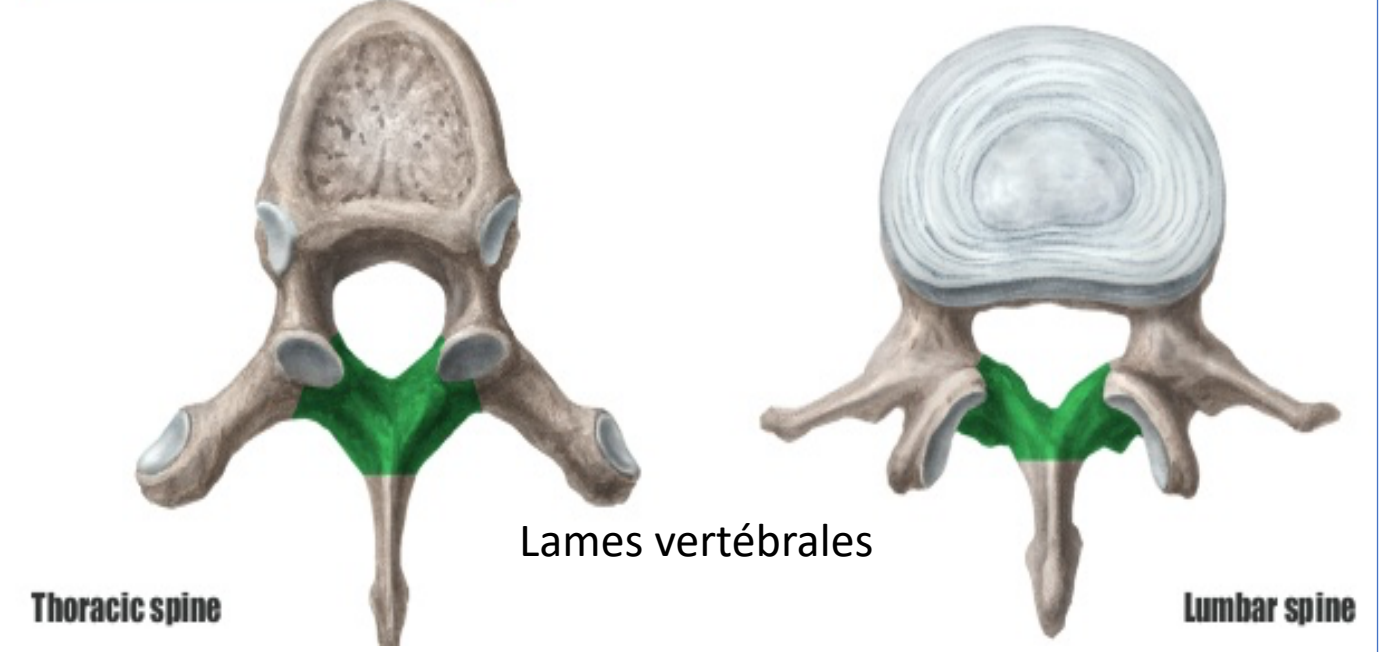
Lames vertébrales
Thoracic spine
Lumbar spine

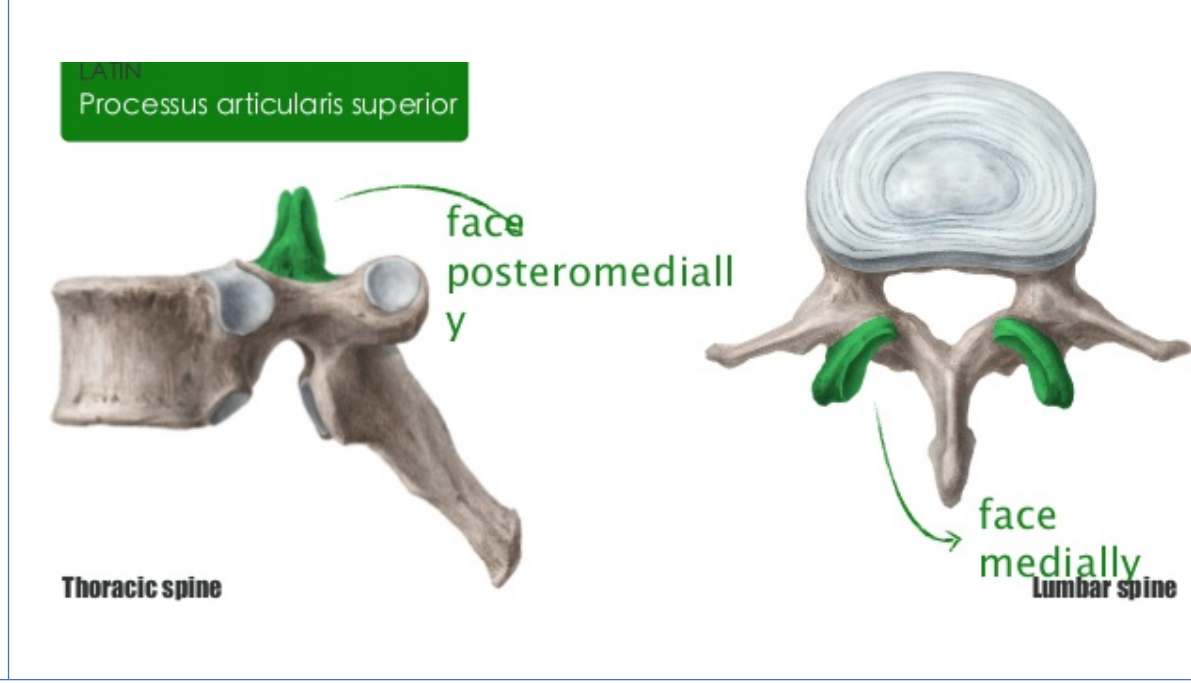
LATIN
Processus articularis superior
face posteromediall y
face medially
Thoracic spine
Lumbar spine

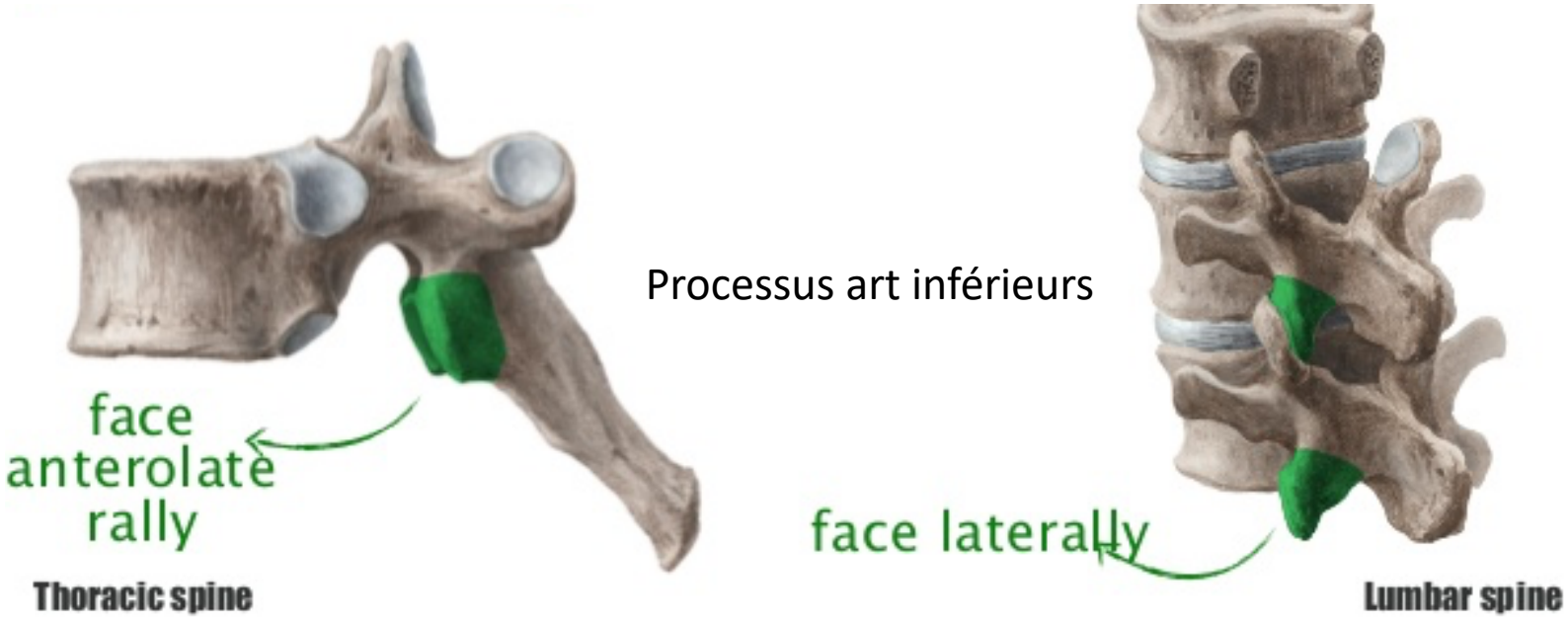
Processus art inférieurs
face anterolate rally
face laterally
Thoracic spine
Lumbar spine

T4

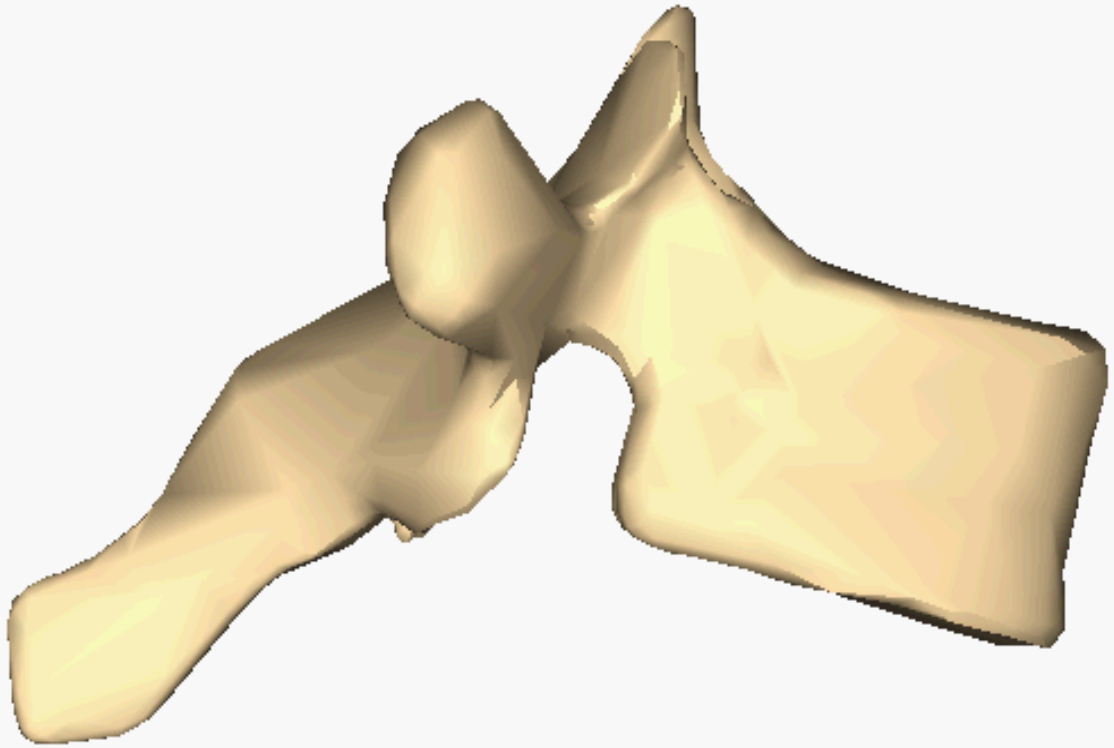

T7



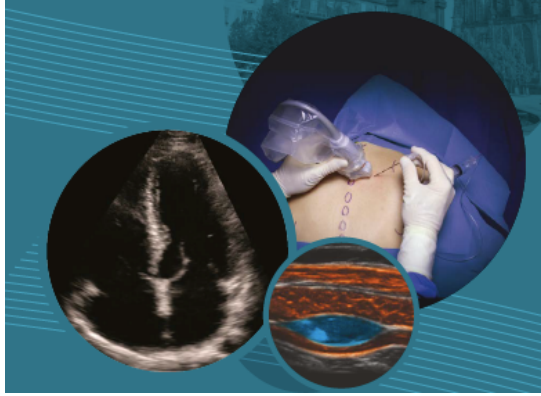

Niveau de ponction

Progression sagittale caudo-apicale

Repérage niveau costal
XII vers VI/VII jonction côte/AT

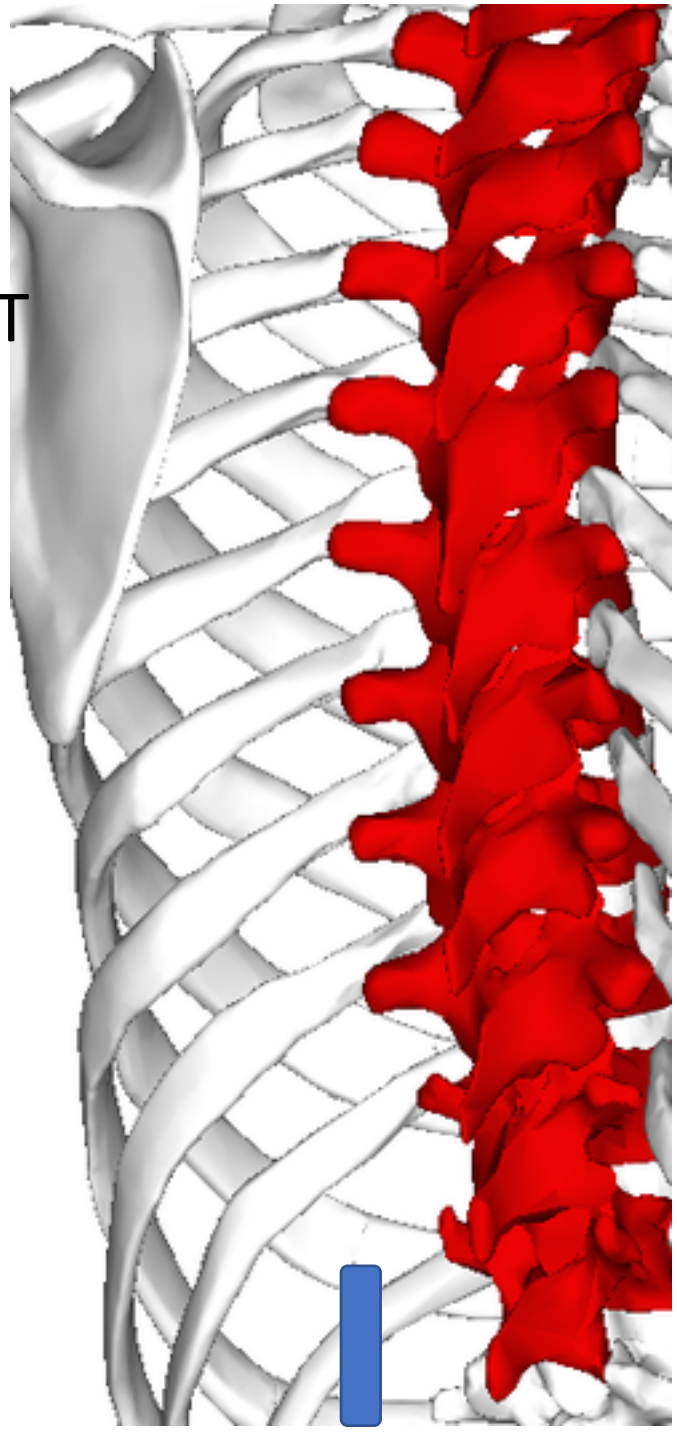

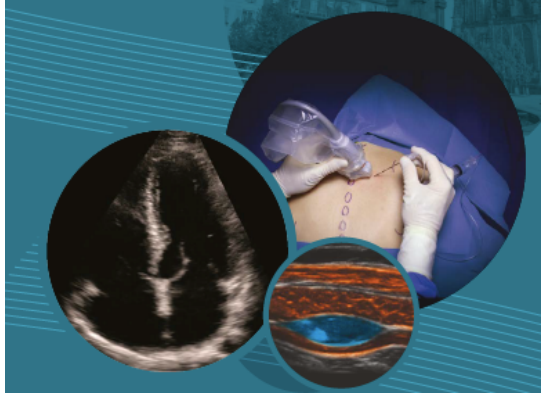

Orientation et optimisation de l’image

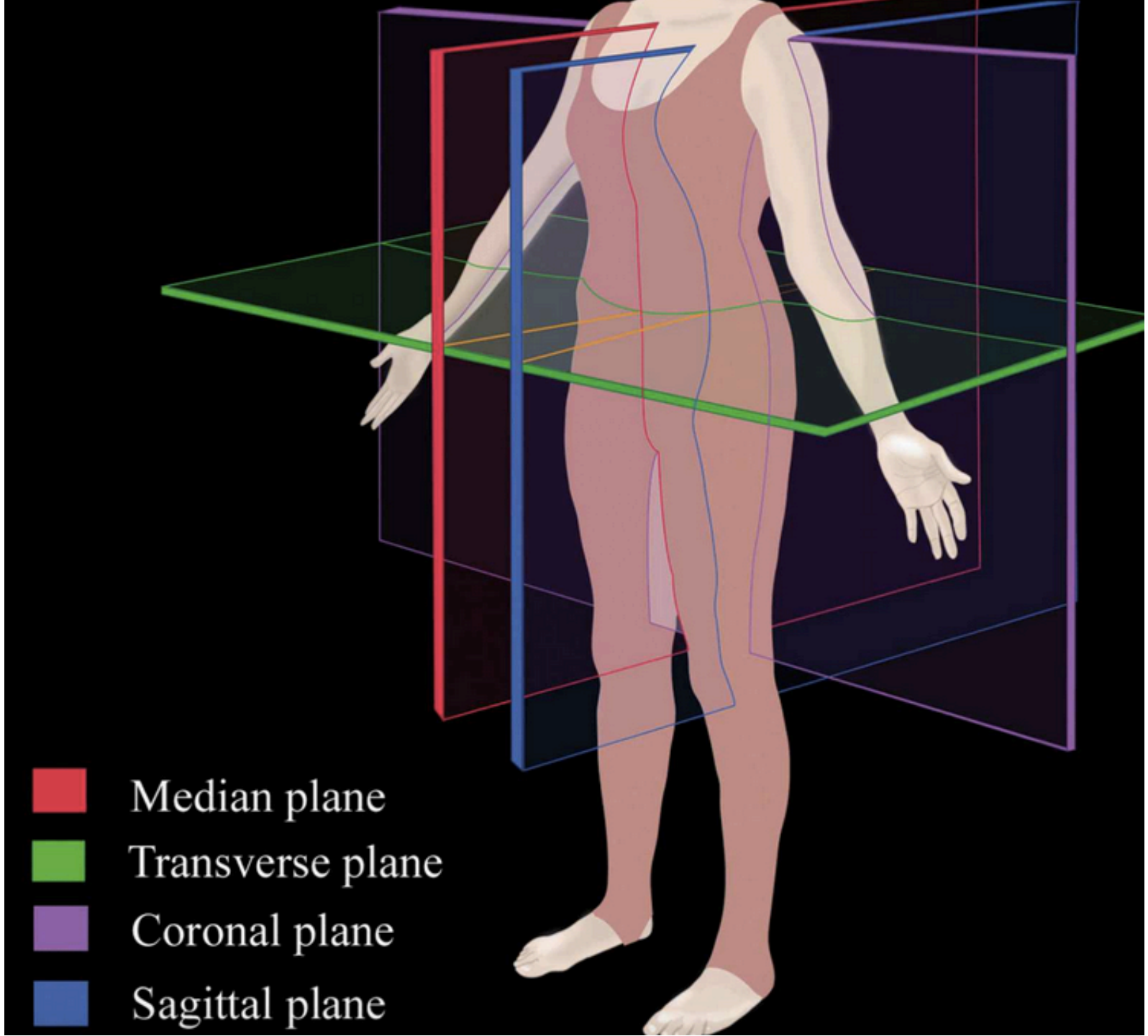
Median plane
Transverse plane
Coronal plane
Sagittal plane

2 ParaM sagittal (Part)

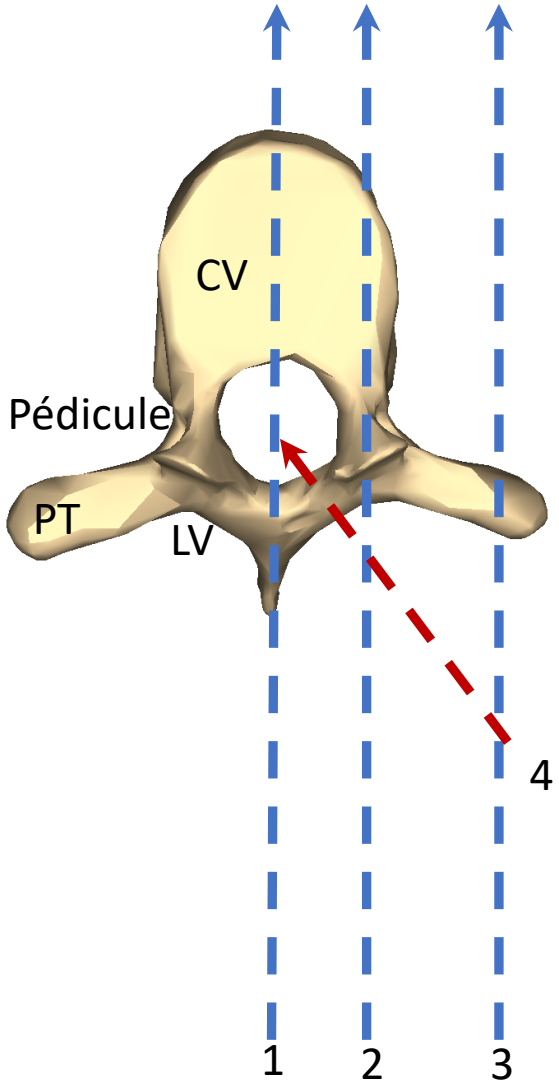
CV
Pédicule
PT
LV
4
1
2
3

3 ParaM sagittal (PT)

1 sagittale médiane

4 ParaM sagittal oblique

Rachis thoracique: optimisation parasagitale oblique

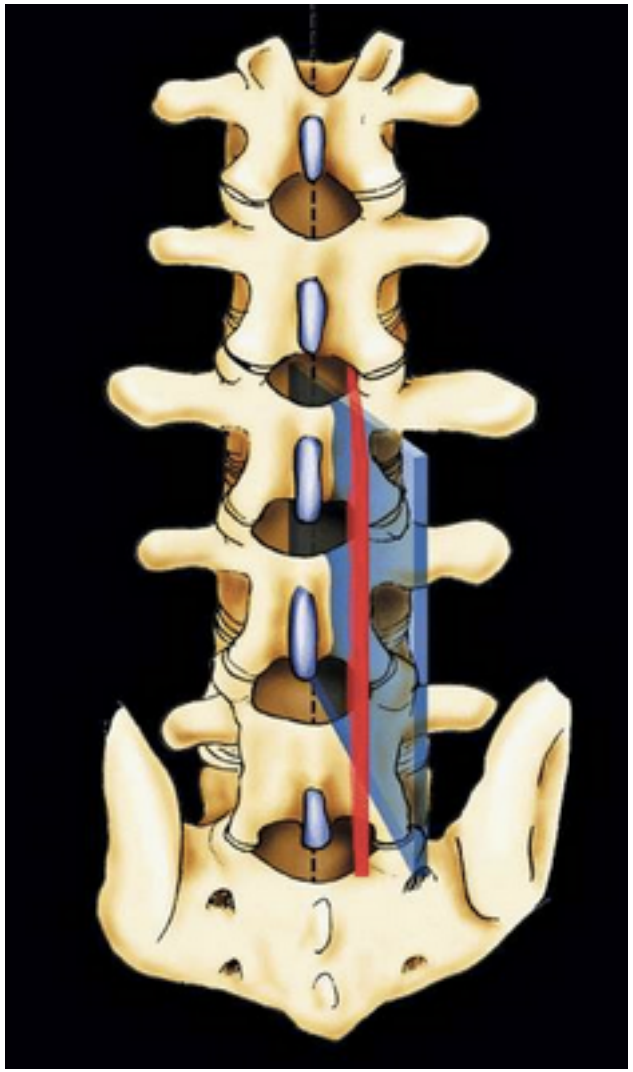

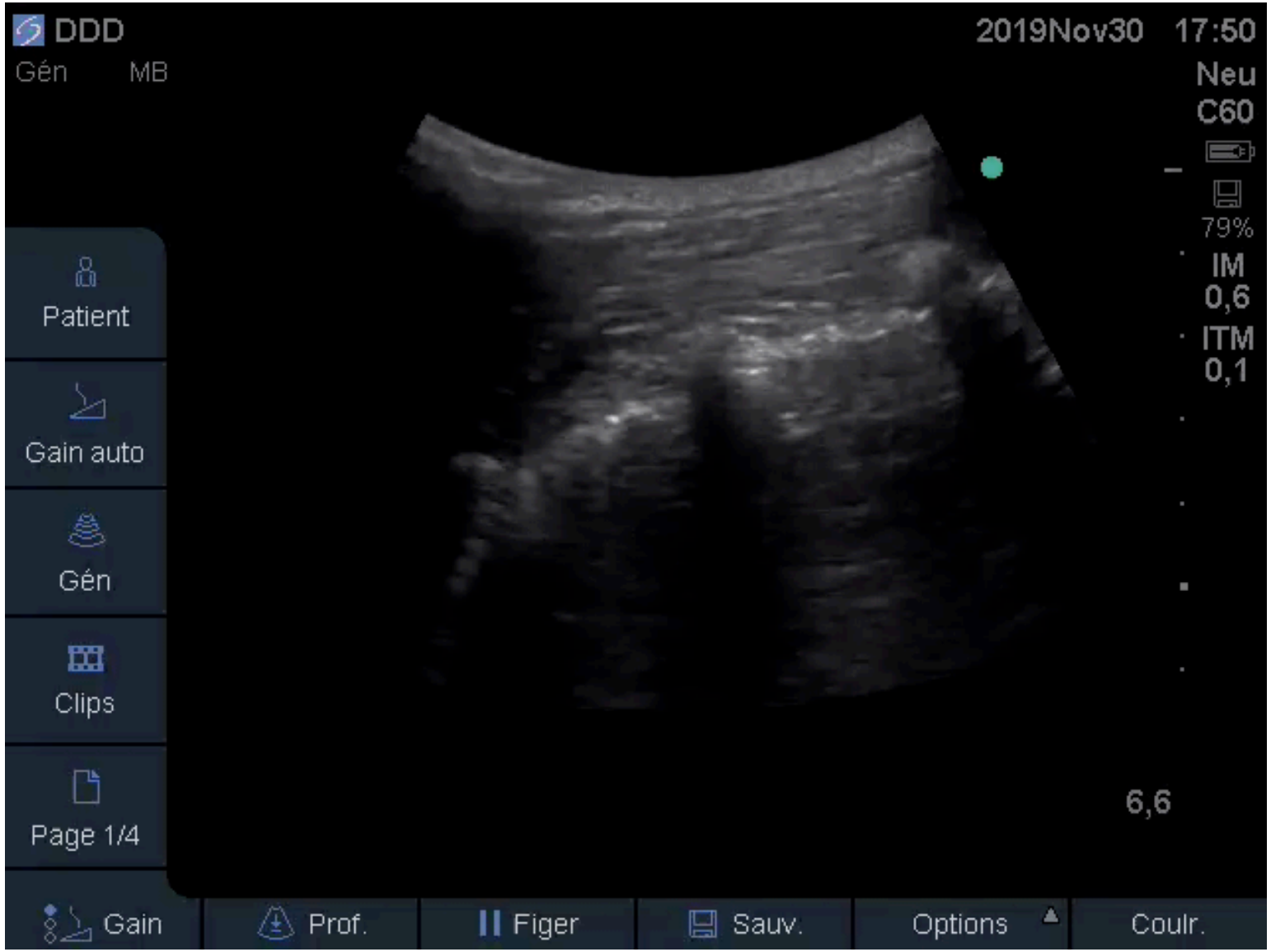

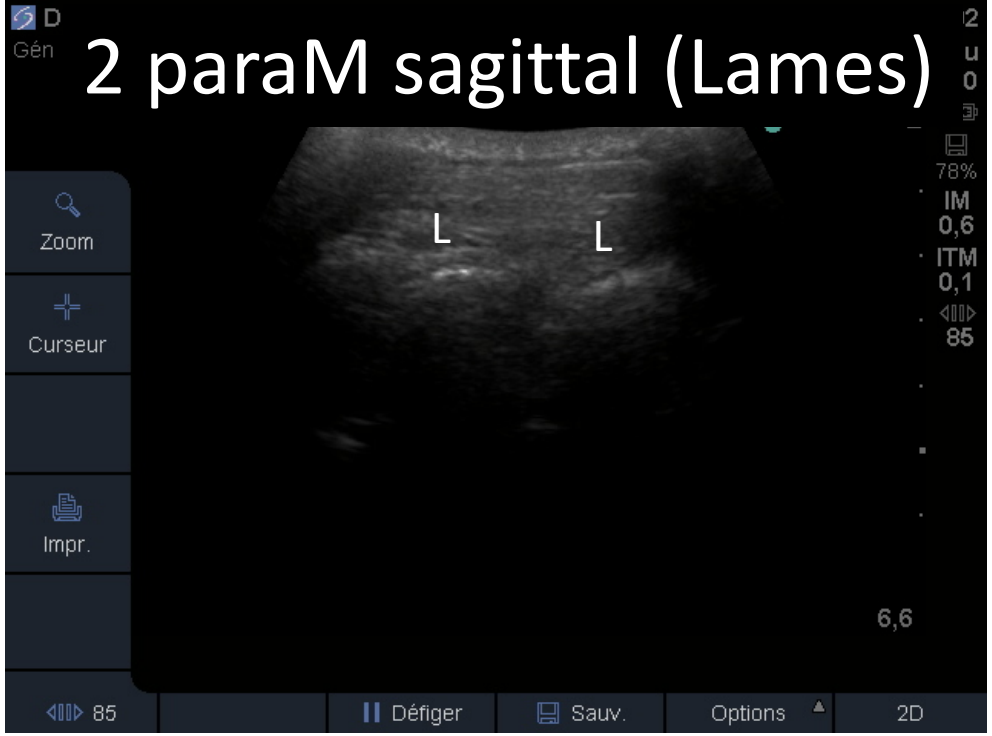
2 paraM sagittal (Lames)
L
L
Zoom
Curseur
Impr.
78%
IM
0,6
ITM
0,1
85
6,6
85
Défiger
Sauv.
Options
2D

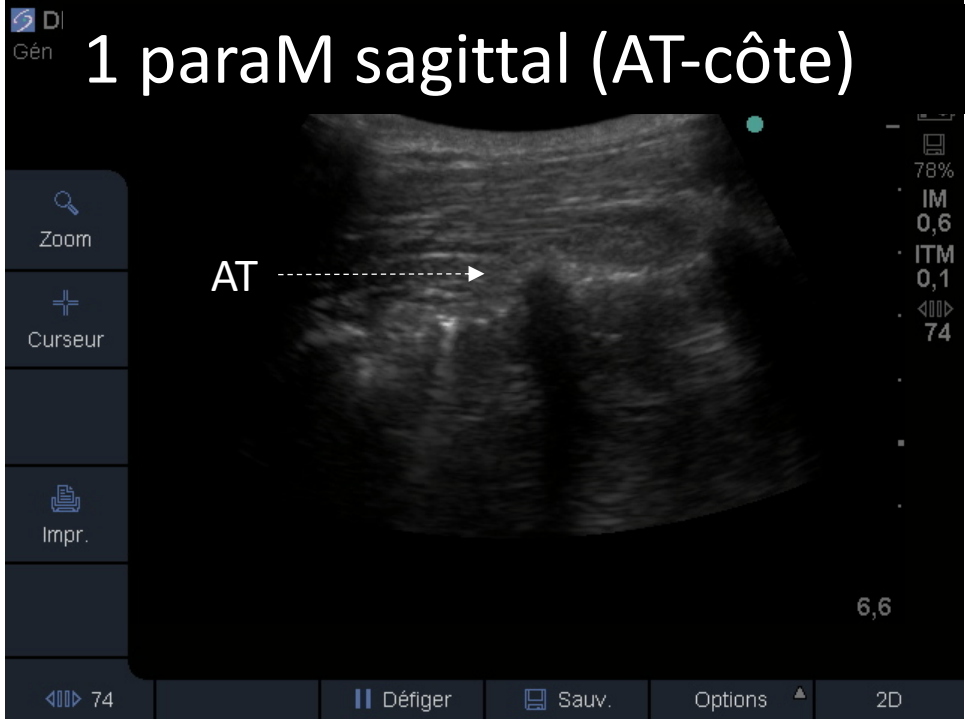
1 paraM sagittal (AT-côte)
AT
Zoom
Curseur
Impr.
78%
IM
0,6
ITM
0,1
74
6,6
74
Défiger
Sauv.
Options
2D

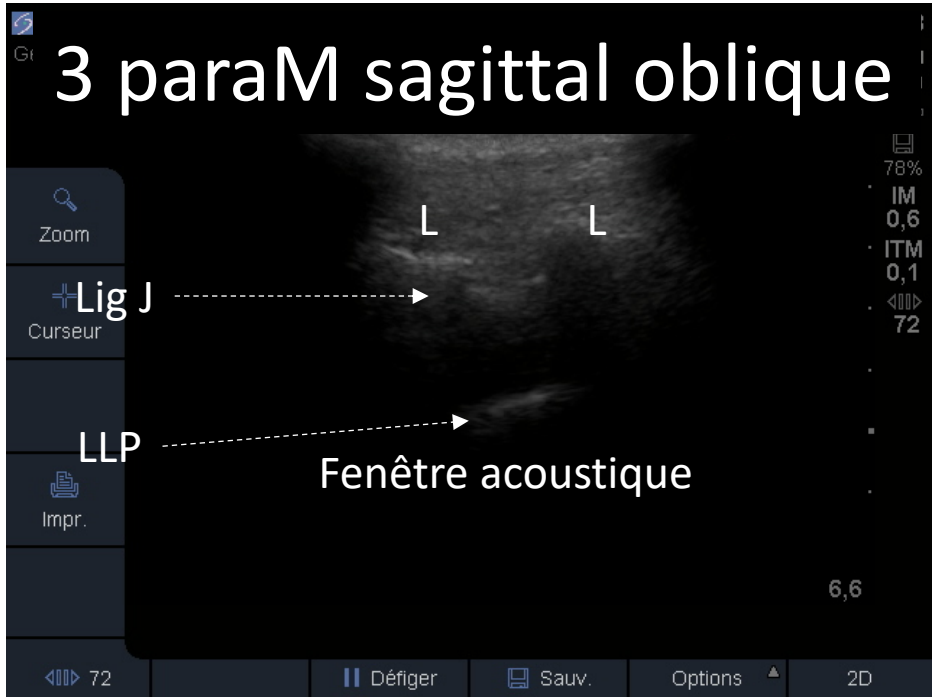
3 paraM sagittal oblique
L
L
Lig J
LLP
Fenêtre acoustique
Zoom
Curseur
Impr.
78%
IM
0,6
ITM
0,1
72
6,6
72
Défiger
Sauv.
Options
2D

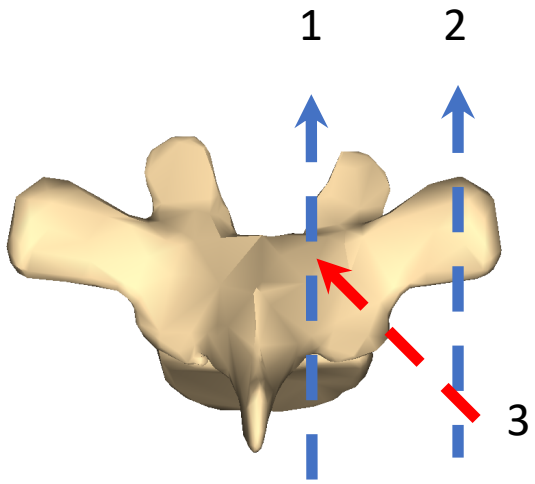
1
2
3

Niveau T7

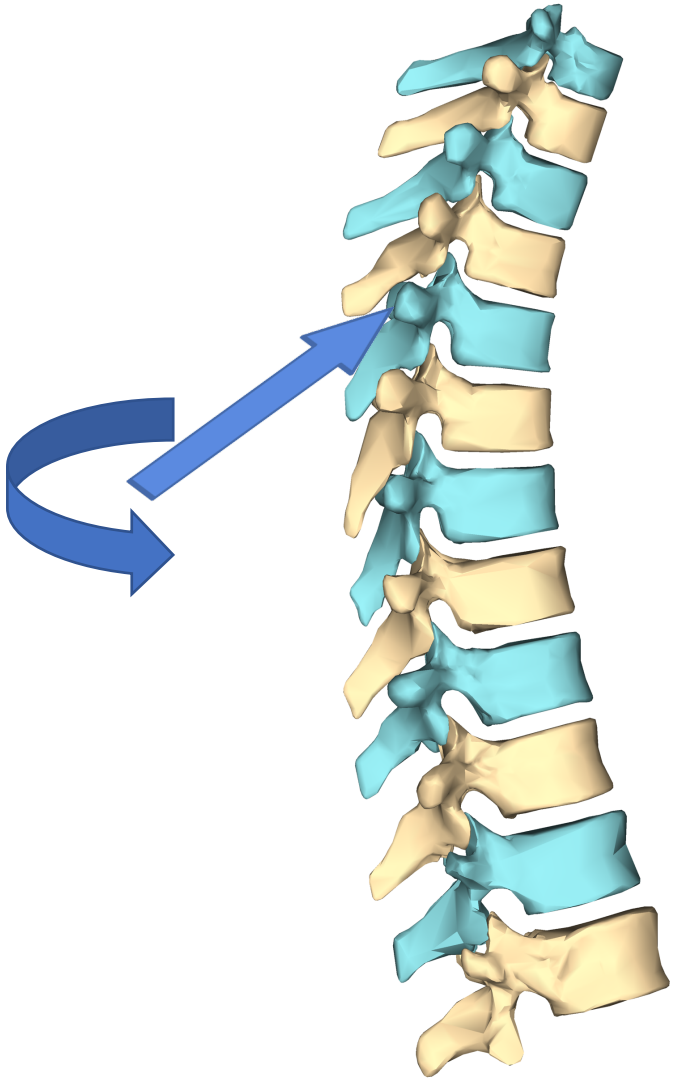

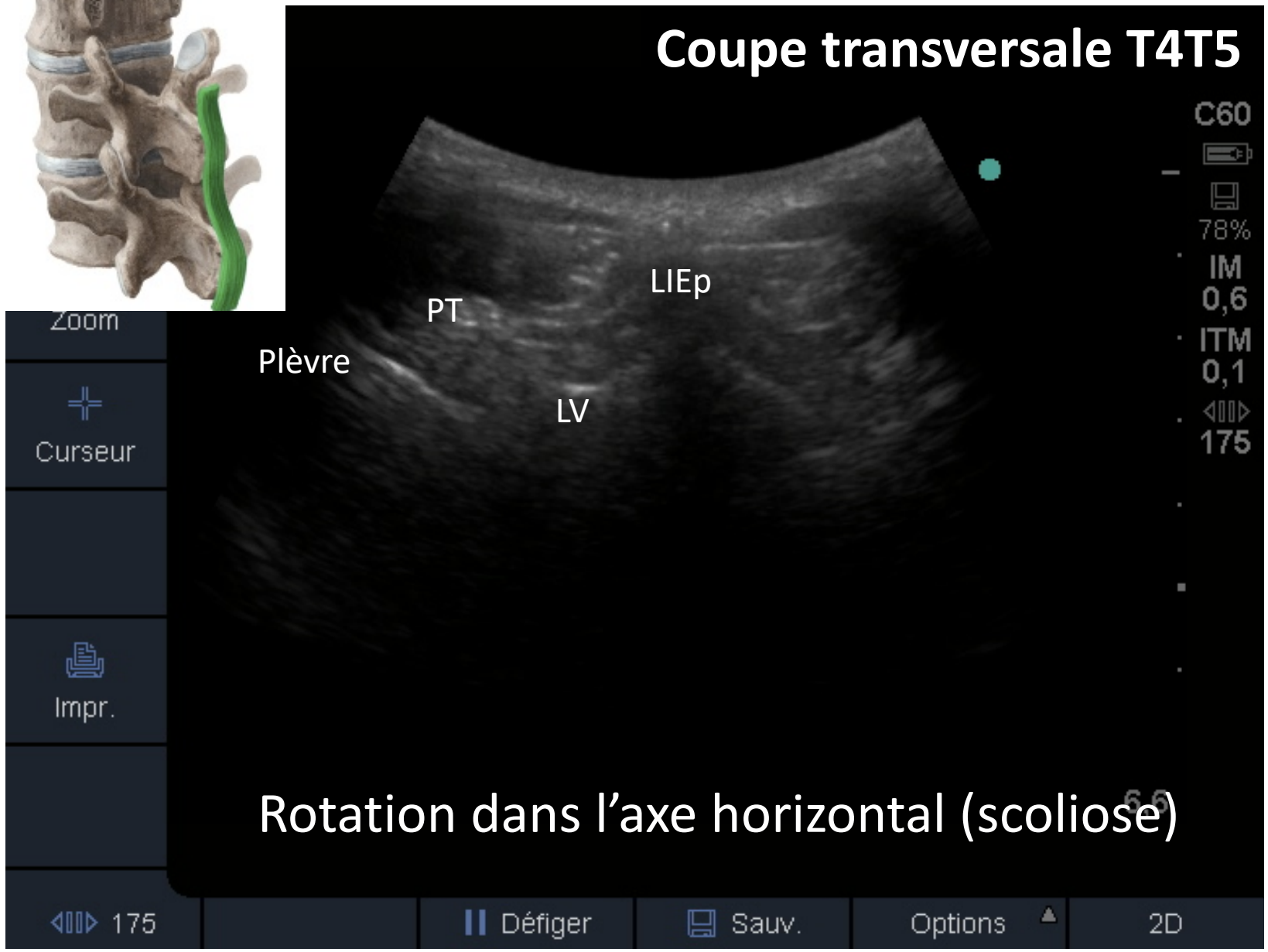
Coupe transversale T4T5
C60
78%
IM
0,6
ITM
0,1
175
LIEp
PT
Plèvre
LV
Zoom
Curseur
Impr.
Rotation dans l'axe horizontal (scoliose)
175
Défiger
Sauv.
Options
2D

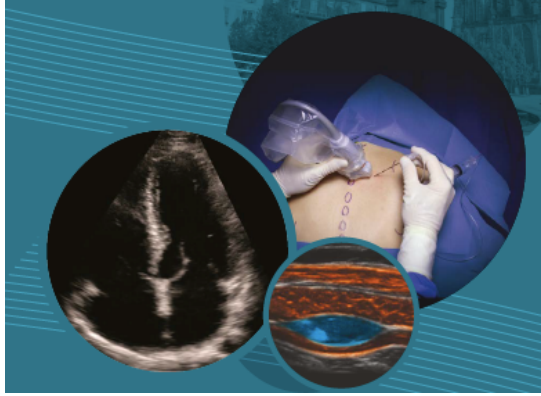

Données cliniques

Ultrasound Imaging of the Thoracic Epidural Space

T. Grau, M.D., R.W. Leipold, M.D., S. Delorme, M.D.,
E. Martin, M.D., F.A.N.Z.C.A, and J. Motsch, M.D.

Regional Anesthesia and Pain Medicine, Vol 27, No 2 (March–April), 2002: pp 200–206

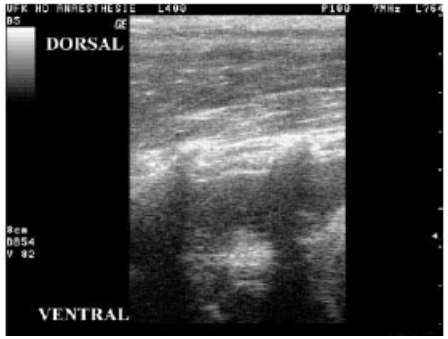

Cohérence entre IRM et US sur les scores de visualisation

T5/T6

(0, invisible; 3, good visibility).

Imaging Plane	Structure	Measurement of	MRI*	USI*	Correlation (r^2)	Bland-Altmann/ 95% (mm)	Dev/Mean (mm)
Transversal	Ligamentum flavum	Depth	31 ± 6.3	31 ± 5.5	0.61	7.9	−0.1
	Spinal space	Depth	37 ± 5.5	33 ± 5.9	0.54	8.4	−0.7
		Lumen	15 ± 1.9	15 ± 3.0	0.18	2.9	+2.1
	Vertebra	Depth	52 ± 7.0	49 ± 5.8	0.68	7.9	−3.0
Median longitudinal	Ligamentum flavum	Depth	33 ± 6.2	32 ± 4.4	0.54	8.4	−0.7
	Dura mater	Depth (dorsal)	39 ± 5.4	37 ± 4.3	0.79	4.9	−1.9
		Depth (ventral)	51 ± 6.0	49 ± 5.3	0.85	4.6	−2.1
	Spinal space	Depth	39 ± 5.3	37 ± 4.3	0.53	7.9	−0.3
		Lumen	13 ± 2.4	16 ± 2.9	0.11	5.7	−1.4
	Vertebra	Depth	53 ± 6.0	51 ± 5.6	0.77	5.7	−1.4
		Height	26 ± 3.7	27 ± 2.5	0.22	7.1	+0.2
Paramedian longitudinal	Ligamentum flavum	Depth	36 ± 5.6	32 ± 4.3	0.53	6.5	−4.1
	Dura mater	Depth (dorsal)	41 ± 4.9	37 ± 4.1	0.57	6.4	−4.1
		Depth (ventral)	53 ± 4.7	50 ± 5.7	0.73	5.9	−3.2
	Spinal space	Depth	41 ± 5.0	36 ± 4.6	0.44	7.8	−4.7
		Lumen	15 ± 3.6	18 ± 3.6	0.30	6.7	+3.2
	Vertebra	Depth	54 ± 5.3	53 ± 5.2	0.42	8.7	−0.9
		Height	27 ± 4.0	29 ± 3.6	0.50	5.8	+1.6

Utility of prepuncture ultrasound for localization of the thoracic epidural space

Abtin Rasoulian, MSc · Jens Lohser, MD · Mohammad Najafi, MSc · Hedyeh Rafii-Tari, BASc · Denis Tran, PhD · Allaudin A. Kamani, MD · Victoria A. Lessoway, RDMS · Purang Abolmaesumi, PhD · Robert N. Rohling, PhD

Can J Anesth/J Can Anesth (2011) 58:815–823

Sous-estimation faible avec US des distances mesurées, incidence sagittale paramédiane oblique

The vertebral level determined by the clinicians was always either equal to or higher than the level determined by the sonographer. The identified levels matched in only 40% of cases; they differed by one level in another 40% of cases, and they differed by two levels in the remaining 20% of cases.

		US-CT	CT-Needle	US-Needle
Bias		2.99	0.2	3.21
95% limits of agreement	Lower	−7.29	−10.7	−7.47
	Upper	13.28	11.1	13.90
R^2		0.69	0.58	0.65
Average of absolute difference (mm)		4.49	4.55	4.68

Pression effectuée par la sonde
CT-IRM: visualisation complète
US: fenêtre acoustique seule utilisable
Epaisseur des tissus cibles mesurées
Angulation

REGIONAL ANESTHESIA AND ACUTE PAIN

BRIEF TECHNICAL REPORT

Real-Time Ultrasound-Assisted Thoracic Epidural Placement

A Feasibility Study of a Novel Technique

Daniel J. Pak, MD and Amitabh Gulati, MD†*

Reg Anesth Pain Med 2018;43: 613–615

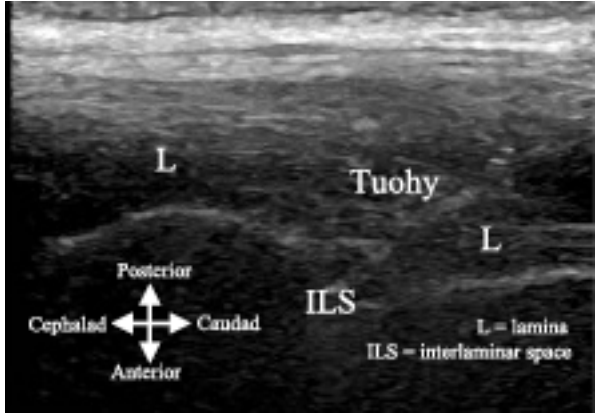

abdominal or thoracic surgery at a single institution.[12] We review the results of our technique in the first 15 patients in a teaching institution regarding the feasibility of this technique and whether it

Location	
T7–T8	7 (46.7%)
T8–T9	7 (46.7%)
T9–T10	1 (6.6%)
T10–T11	0
Repérage → Midazolam to lidocaine infiltration time, min	5 ± 4.4 (1–19)
Ponction → Lidocaine to test dose time, min	10 ± 7.0 (4–25)
Single needle insertion	11/15 (73.3%)
Needle redirection	13/15 (86.7%)

Evaluation of Ultrasound-Assisted Thoracic Epidural Placement in Patients Undergoing Upper Abdominal and Thoracic Surgery

A Randomized, Double-Blind Study

David B. Auyong, MD, Lucy Hostetter, MD,* Stanley C. Yuan, MD,* April E. Slee, MS,† and Neil A. Hanson, MD**

Reg Anesth Pain Med 2017;42: 204–209

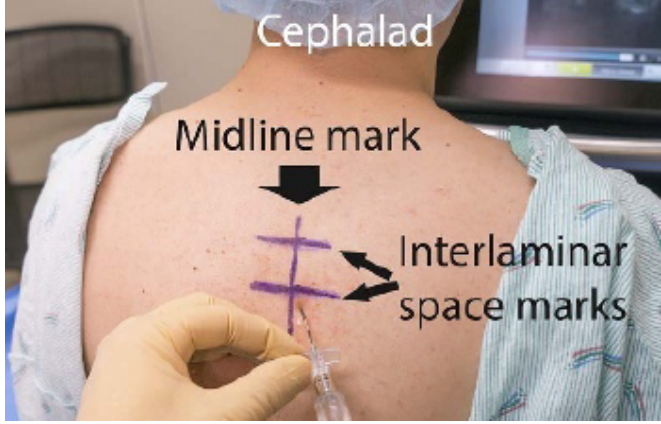

	Ultrasound Group (n = 33)	Palpation Group (n = 37)	*P*
Needling time, seconds (primary outcome)	188.50 [72.5–515.0]	242.0 [87.0–627.0]	0.188
Time to mark spaces, seconds	85.0 [69.0–113]	35.0 [27.0–51.0]	<0.001*
Number of needle passes	2.0 [1.0–5.0]	3.0 [2.0–7.0]	0.085
Number of skin			0.005*
1			
2			
≥3			
Ease of threadi			0.115
Easy			
Difficult			
Working epidural per blinded assessment			0.353
Yes	29 (87.9%)	29 (78.4%)	
No	4 (12.1%)	8 (21.6%)	
NRS PACU Pain score (0–10)	3.00 ± 2.82	4.68 ± 2.82	0.015*

Subdividing the groups based on obesity (body mass index ≥ 30 kg/m^2), the median time to epidural LOR in obese versus nonobese was 205.0 seconds (IQR, 77.0–611.0) and 223.5 seconds (IQR, 79.0–536.0), respectively ($P = 0.863$). As clinical thresholds

Ultrasound-Assisted Technology Versus the Conventional Landmark Location Method in Spinal Anesthesia for Cesarean Delivery in Obese Parturients: A Randomized Controlled Trial

Mengzhu Li, MD, Xiu Ni, MD, Zhendong Xu, PhD, Fuying Shen, MD, Yingcai Song, MD, Qian Li, MD, and Zhiqiang Liu, PhD

Bénéfice des US avant APD lombaire avec obésité

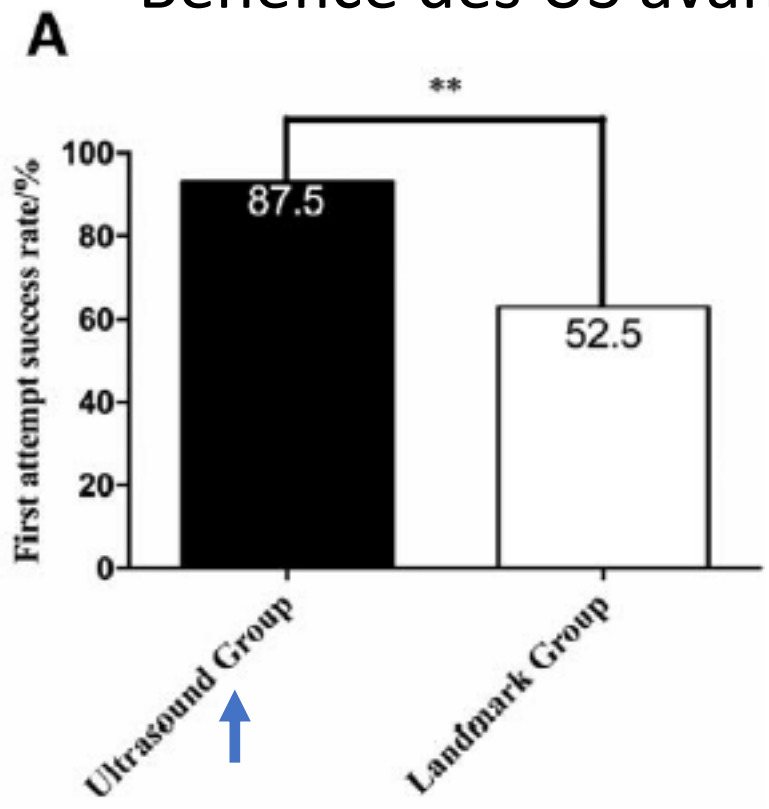

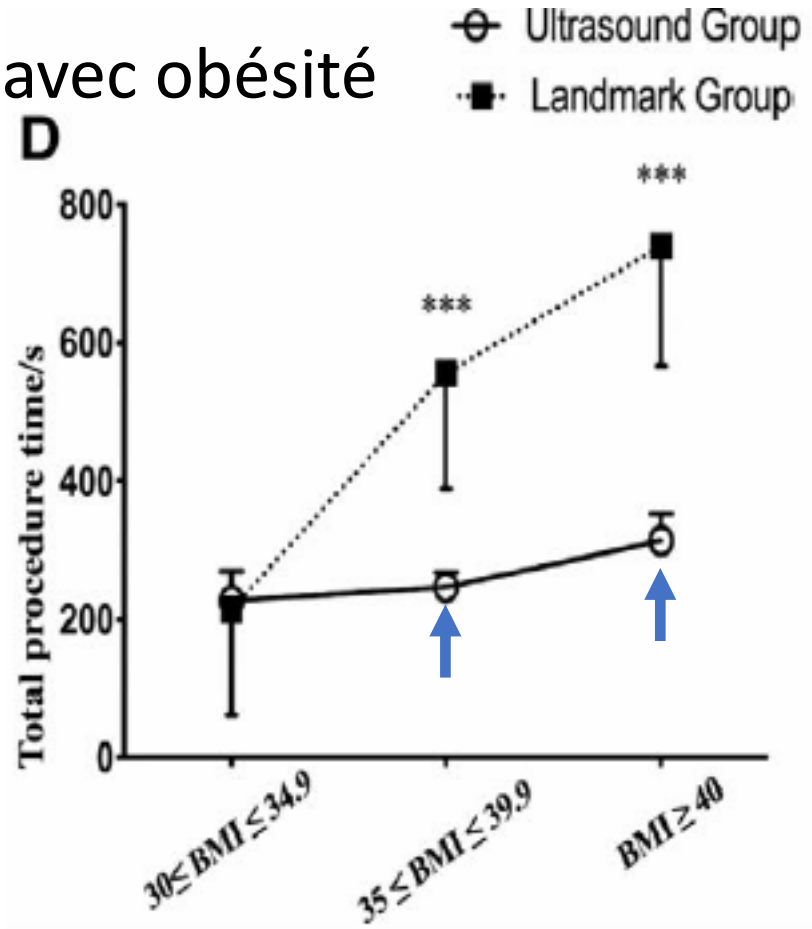

Anesth Analg. 2019 Jul;129(1):155-161.

Bénéfice accru avec augmentation de l'IMC

	Ultrasound Group	Landmark Group	*P* Value
First-attempt success rate[a]			
30 kg/m² ≤ BMI ≤ 34.9 kg/m²	17/19 (89.5)	15/20 (75)	.407[b]
35 kg/m² ≤ BMI ≤ 39.9 kg/m²	12/13 (92.3)	5/13 (38.5)	.011[b]
BMI ≥40 kg/m²	6/8 (75)	1/7 (14.3)	.041[c]
>10 needle passes[d]			
30 kg/m² ≤ BMI ≤ 34.9 kg/m²	0	3/20 (15)	.231[c]
35 kg/m² ≤ BMI ≤39.9 kg/m²	0	8/13 (61.5)	.002[c]
BMI ≥40 kg/m²	1/8 (12.5)	6/7 (85.7)	.010[c]

Anesth Analg. 2019 Jul;129(1):155-161.

Epidural catheter placement in children: comparing a novel approach using ultrasound guidance and a standard loss-of-resistance technique

H. Willschke[1], P. Marhofer[1]*, A. Bösenberg[2], S. Johnston[2], O. Wanzel[3], C. Sitzwohl[1], S. Kettner[1] and S. Kapral[1]

British Journal of Anaesthesia **97** (2): 200–7 (2006)

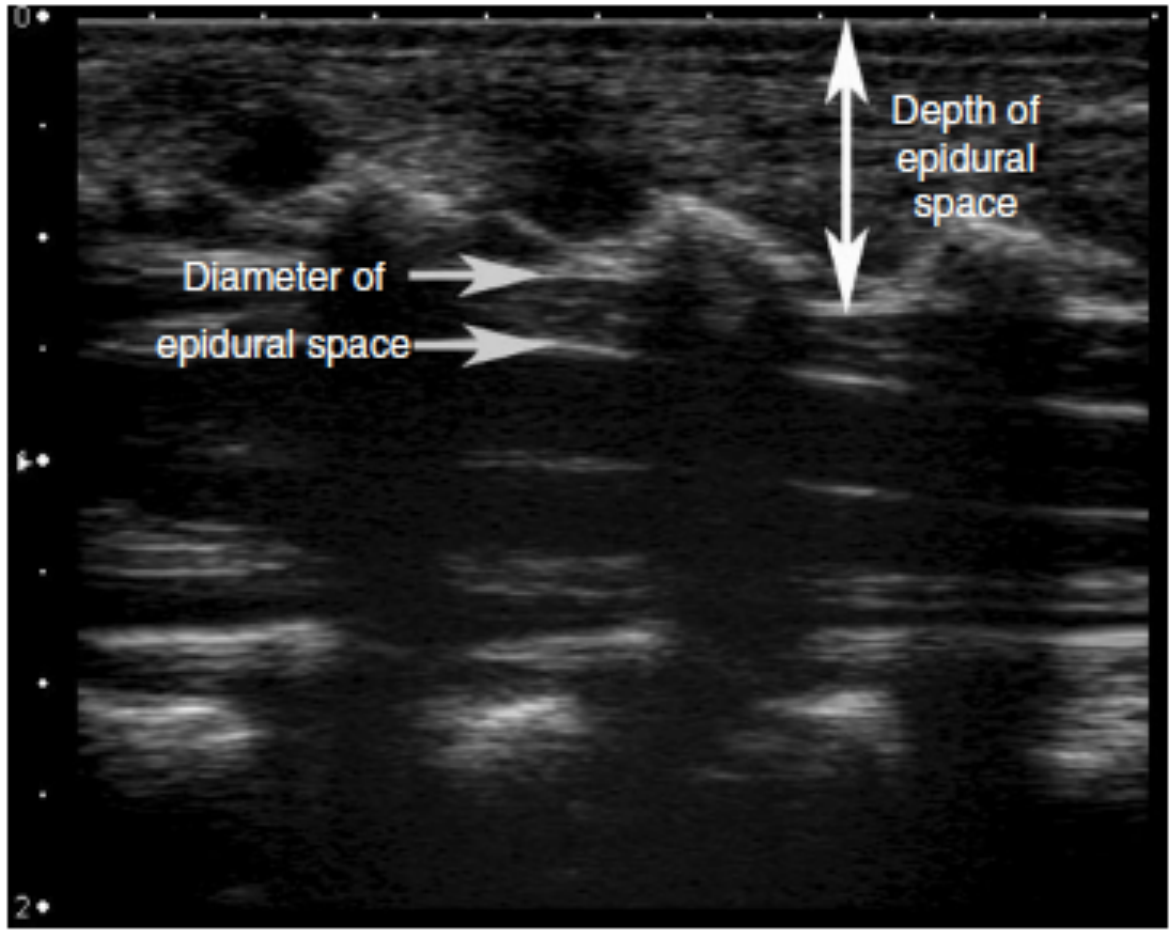

Échoguidage chez l'enfant > 6 mois

	Ultrasound group	Control group (LOR technique)	*P*-value
Patients (*n*)	11	21	
Age (months)	14.1 (14.0–84.0)	12.3 (9.0–84.0)	
Body weight (kg)	42.0 (7.9–23.3)	34.3 (4.9–24.0)	
Thoracic puncture (*n*)	11	21	
Lumbar puncture (*n*)	0	0	
Skin to epidural space* (mm)	13.5 (3.3)		
Diameter of epidural space* (mm)	3.2 (0.9)		
Time to perform epidural (s)	142 (49)	286 (145)	<0.01
Percentage of epidural punctures with bone contacts† (%)	9	89	<0.01

Ultrasound-assisted thoracic epidural puncture: A paramedial-lateral approach

ShengJin Ge (MD PhD)*, YuanYuan Ma (MD), YuYing Yang (MD)

Journal of Clinical Anesthesia 59 (2020) 69–71

Abord sonde en position transverse jusqu’à disparition aiguille (ombre épineuse)

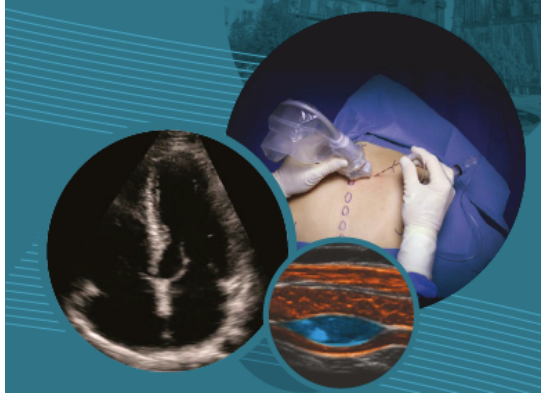

Amélioration de la fenêtre acoustique

Identification ligament longitudinal postérieur

ORIGINAL ARTICLE

Evaluation of pre-procedure ultrasound examination as a screening tool for difficult spinal anaesthesia*

J. T. Weed,[1] A. H. Taenzer,[2] K. J. Finkel[3] and B. D. Sites[4]

Anaesthesia, 2011, **66**, pages 925–930

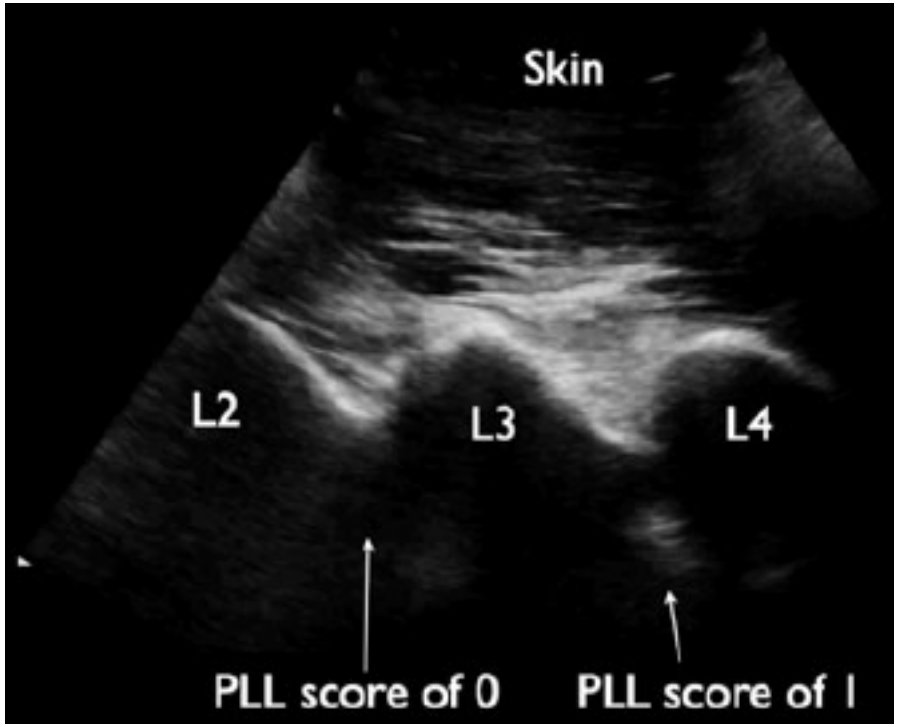

Score de visualisation du LLP ≤8/16 et prédiction du risque de ponction rachidienne difficile

Sensitivity	50.0%
Specificity	90.6%
Positive predictive value	82.3%
Negative predictive value	67.4%
Positive likelihood ratio	12.8
Negative likelihood ratio	0.55

Flexion-rotation manoeuvre increases dimension of the acoustic target window for paramedian thoracic epidural access

N. Ramsay, J. Walker, R. Tang, H. Vaghadia* and A. Sawka

British Journal of Anaesthesia **112** (3): 556–62 (2014)

P1. Neutral: no back flexion/extension.

P2. Flexion: slouching of the shoulders with lumbar flexion and exaggeration of the thoracic kyphosis with arms around a pillow at chest level.

P3. Table tilt: as in position 2 and dorsal table tilt to 10°.

P4. Right rotation: as in position 2 and 45° rightward shoulder rotation.

P5. Left rotation: as in position 2 and 45° leftward shoulder rotation.

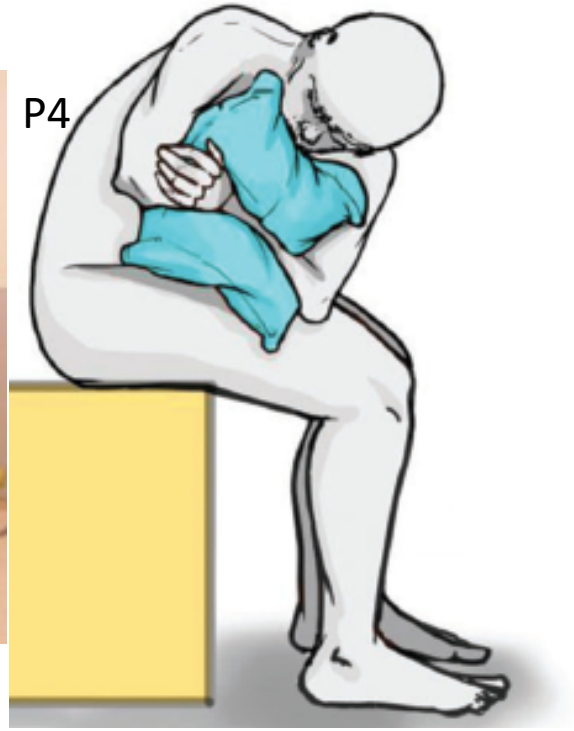

Objectif: élargir la cible acoustique par une ouverture rachidienne

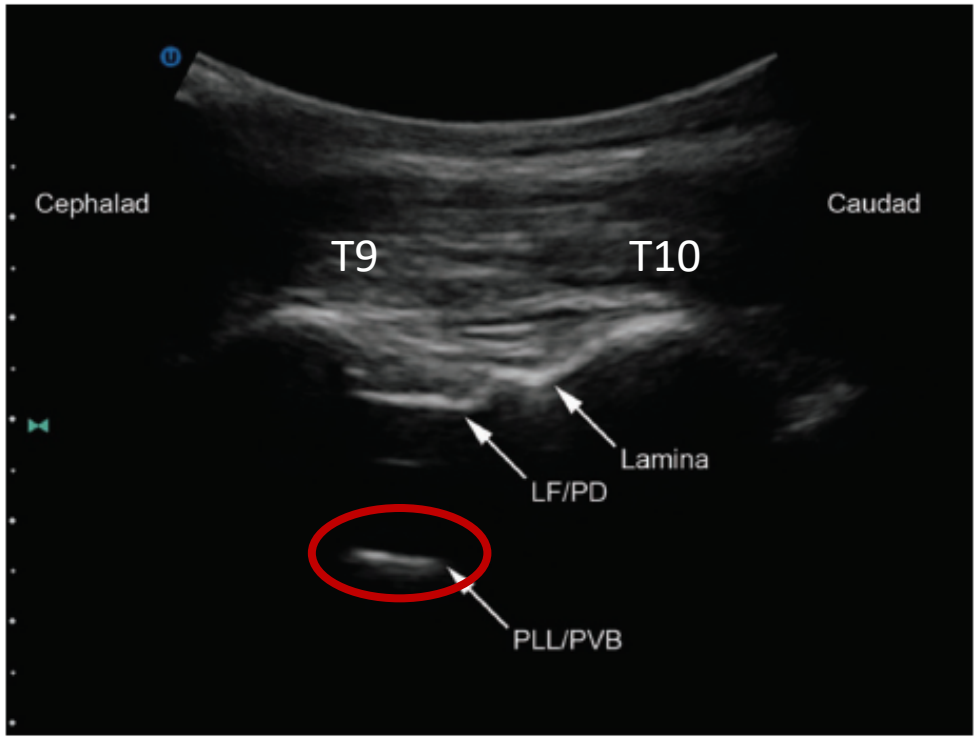

Volunteer position	P1 (Neutral)	P2 (PA flexion)	P3 (PA flexion and dorsal table tilt to 10°)	P4 (PA flexion and right (ipsilateral rotation)	P5 (PA flexion and left (contralateral rotation)
Posterior longitudinal ligament length	9.9 (3.958)	11.79 (3.427)	12.9 (3.144)	13.83 (4.027)	11.14 (3.159)
P-value compared with position P1		<0.01	<0.01	<0.01	<0.05
P-value compared with position P2	<0.01		<0.01	<0.01	0.1

British Journal of Anaesthesia **112** (3): 556–62 (2014)

Original Article

Comparison of the acoustic windows for the thoracic paramedian epidural approach after shoulder rotation: The lateral decubitus versus the sitting position

Hyo-Jin Byon [a], Sung-Jun Hong [b], Dae-Yu Kim [b], Joo-Hyeon O [b], In-Gon Lee [b], Dong-Ho Seo [b], Gyoung-A. Heo [c], Hyunzu Kim [c,*]

H.-J. Byon et al. / Anaesth Crit Care Pain Med 38 (2019) 53–56

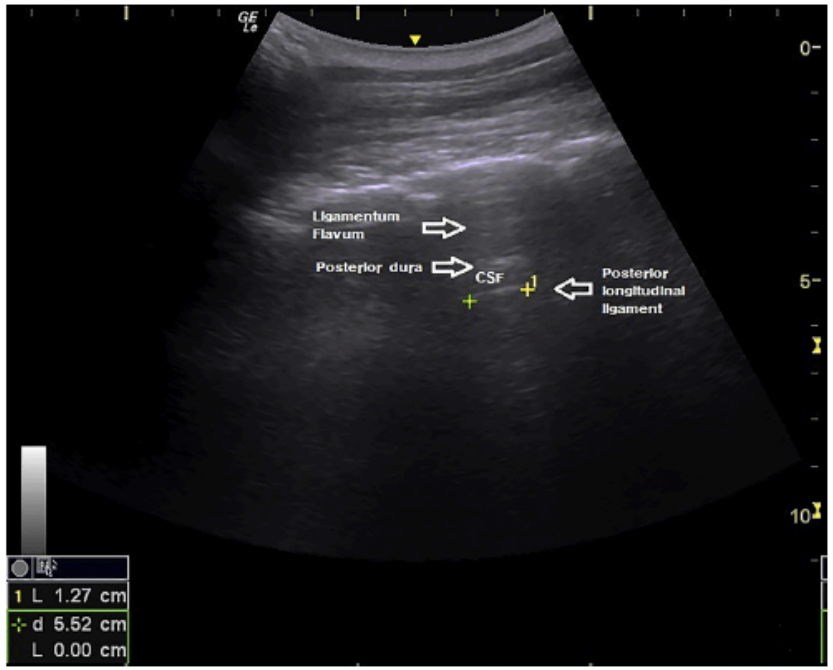

T6/T7

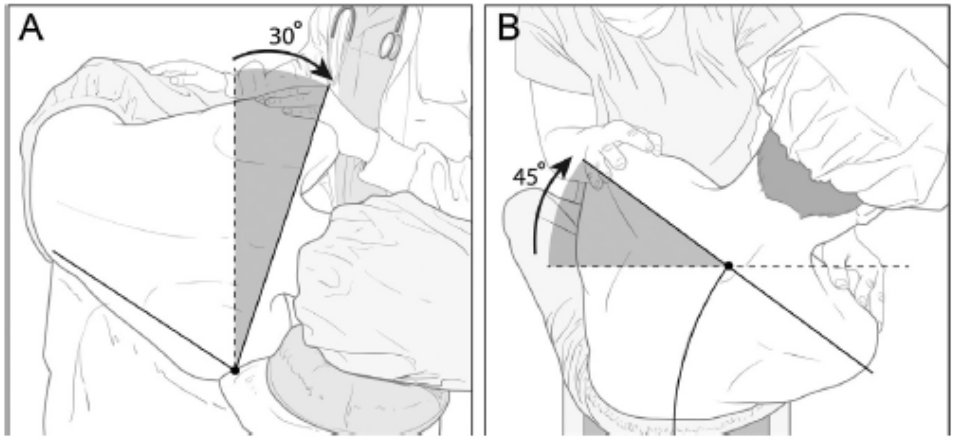

Bénéfice de la rotation épaule

	Mean (SD)	*P* value[a]	*P* value[b]
Before shoulder rotation (mm)			
Sitting position	11.1 (1.3)		
Lateral decubitus position	10.7 (1.2)	0.05	
After shoulder rotation (mm)			
Sitting position	12.2 (1.4)		<0.001
Lateral decubitus position	12.0 (1.5)	0.50	<0.001

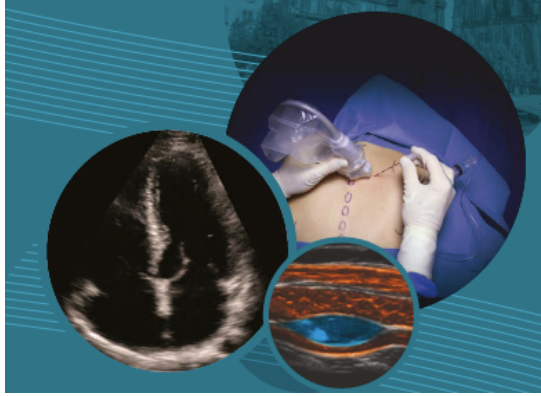

Apprentissage

Anaesth Intensive Care 2014; 42: 480–486

CUSUM method for construction of trainee spinal ultrasound learning curves following standardised teaching

A. J. DEACON*, N. S. MELHUISH†, N. C. S. TERBLANCHE‡

- L5/S1 à L1/L2: 5 [1-9] procédures
- Mesure complexe post: 10 [1-42] procédures
- Point de ponction correct: 2/5 compétents (55 procédures)
- Durée de procédure complète: réduction de 9,2sec/10 procédures

The use of ultrasound for lumbar spinous process identification: A pilot study

Stephen H. Halpern, MD · Arnab Banerjee, MBBS · Renato Stocche, MD, PhD · Phyllis Glanc, MD

Can J Anesth/J Can Anesth (2010) 57:817–822

Objectif: ≥90% succès niveau intervertébral

24%: un niveau au dessus

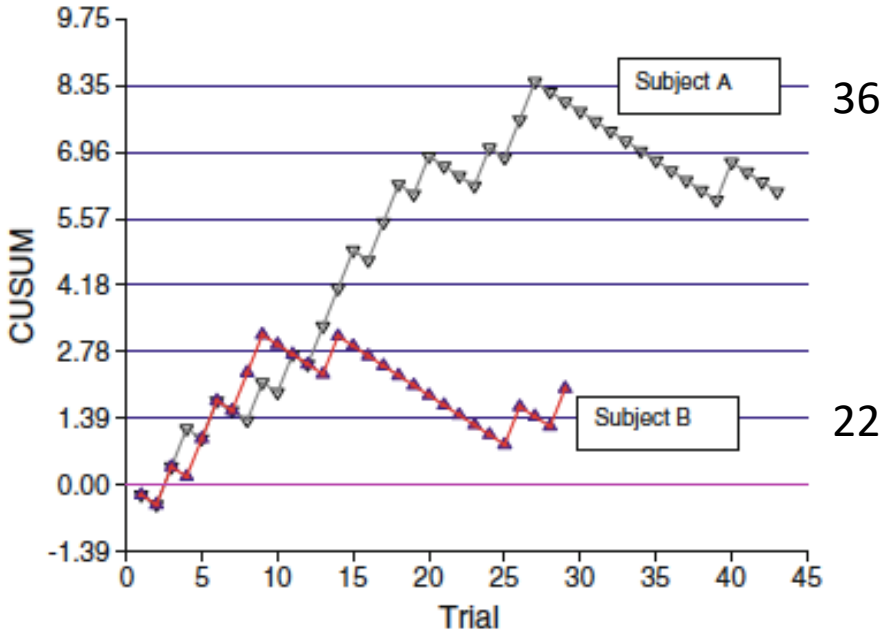

Approche pragmatique

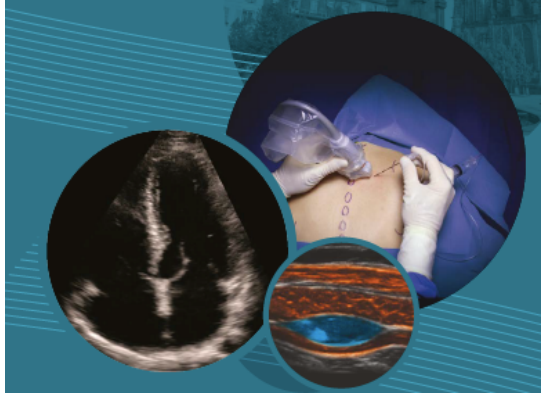

Echorepérage

- Sonde basse fréquence (adulte), mode B, profondeur – gain
- Niveau de ponction (12ème côte → apex ou L5/S1 → apex)
- Paramédian sagittal (Ap Transverse, Ap articulaire, lames vertébrales) puis oblique (lames, ligament jaune, Ligt longitudinal postérieur)
- Transverse (rotation axe vertébral)
- Fenêtre acoustique optimisée (rotation épaule et flexion-tilt postérieure)

Echoguidage

- Courbe apprentissage ++
- Approche paramédiane oblique privilégiée
- Asepsie rigoureuse (gaine)
- Rotation épaule + flexion rachis ?